

ARTICLE

Micronodular thymic carcinoma with lymphoid hyperplasia : A case report and review of the literature

Yin YIN and Qiwei ZHANG*

The Seventh Affiliated Hospital, Sun Yat-sen University, Shenzhen, Guangdong, PR CHINA

*Corresponding author. Email: 569587848@qq.com, <https://orcid.org/0000-0002-2292-9262>

(Received 19 July 2023; revised 29 July 2023; accepted 18 August 2023; first published online 30 September 2023)

Abstract

Cases of micronodular thymic carcinoma with lymphoid hyperplasia are rare and are easily treated like common thymic carcinoma in clinical treatment. The clinical data of a 64-year-old woman admitted to the Seventh Affiliated Hospital of Sun Yat-sen University who was diagnosed with micronodular thymic carcinoma with lymphatic stroma after surgery are reported, and its characteristics and treatment methods are discussed in combination with literature.

Keywords: thymic carcinoma; lymphoid stroma; B lymphocytes

Micronodular thymic carcinoma is a new subtype included in the WHO classification of thymic carcinoma in 2021, and micronodular thymic carcinoma with lymphoid hyperplasia (MNC) is an extremely rare thymic epithelial tumor, with low-grade malignant behavior, its prognosis data are unknown, and it is easy to be treated as common thymic cancer in clinical treatment. In November 2021, our department admitted a case of MNC, as reported below.

1. Clinical data

The patient, female, 64 years old, was admitted to the Department of Nephrology of our hospital on October 25, 2021 due to "elevated creatinine for 3 years and rash of both lower extremities for more than 3 months", and was admitted to the hospital to complete chest CT examination (Fig.1): nodular high-density foci with a diameter of about 11 mm in the anterior mediastinum were considered. The patient was diagnosed after renal biopsy: chronic nephritic syndrome, thrombotic microangiopathy (TMA) kidney injury, chronic kidney disease stage 3a, and after stable treatment, he was transferred to our department (thoracic surgery) for surgical treatment of mediastinal nodules. Preoperative chest enhanced CT (Fig.2): a nodular slightly high-density foci with clear boundaries and a size of about

12mm x 9mm can be seen in the anterior mediastinum, and the enhanced scan is uniformly and significantly strengthened. Preoperative diagnosis of thymoma without myasthenia. Transxiphoid single-port thoracoscopic enlarged resection of thymus tumors was performed under general anesthesia on November 17, 2021. A 4 cm longitudinal incision under the xiphoid process, an incision protective sleeve is inserted, and the sternum is hooked to lift the sternum. Free retrosternal space, open bilateral mediastinal pleura, see left intrathoracic fibrinous adhesions, and separate adhesions. Starting from the fat of the hypothoid pole and the diaphragm angle of the bilateral thymus, the mediastinal tubercle and hyperplastic thymus are completely removed along the surface of the pericardium and the front of the bilateral phrenic nerve, and attention is paid to protecting the innominate vein. The resection extends to both inferior thyroid poles, the lower end to bilateral diaphragmatic angles, and both sides to the anterior phrenic nerve. Intraoperative freezing suggests: thymoma.

The operation time was 100 minutes and the intraoperative bleeding volume was 10 ml. Postoperative pathology: a piece of gray-yellow tissue was sent for examination, the size was about 4.2 cm × 3 cm × 1.3 cm, and a nodule was seen on the section, the size was about 1.4 cm × 1.2 cm × 1 cm, gray-yellow, medium, and the border was clear. Microscopic: The periphery of the tumor is clear, the tumor cells are arranged in sheets or broad beams, separated by a large number of lymphoid tissues, with the formation of lymphatic follicles and germinal centers, and a small number of lymphocytes scattered in the epithelium. Tumor nuclei vary in size, air permeability and chromatin edge set, nucleoli and nuclear division can be seen. Immunohistochemistry: tumor epithelial CK (+), P63 (+), P40 (+), CK19 (+), CD5 (+), CD117 (+), PAX-8 (a small amount of weak +), CD99 (+), EMA (-), CK20 (-), Ki67 positive rate of about 30%; Lymphatic interstitial CD20 (mature B line +), CD3 (mature T line +), TDT (-), CD1a (-), SALL4 (-). In situ hybridization: EBER(-). Combined with HE morphology and immunohistochemistry, it was diagnosed as: micronodular thymic carcinoma with lymphatic interstitial hyperplasia. Staging: Masaoka-Kogal Phase I.

Bilateral chest drains were removed on day 1 and discharged on day 4. Regular follow-up is recommended after discharge. After surgery, the patient was regularly followed up in the outpatient clinic of the local hospital and recovered well, and there was no recurrence for more than 22 months after surgery.

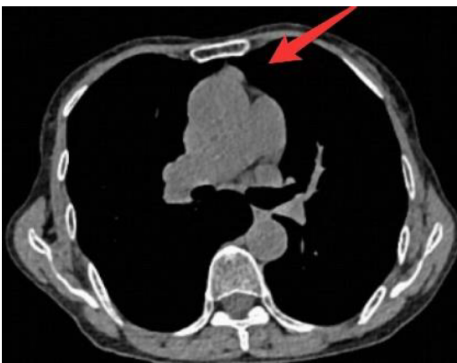


Fig. 1

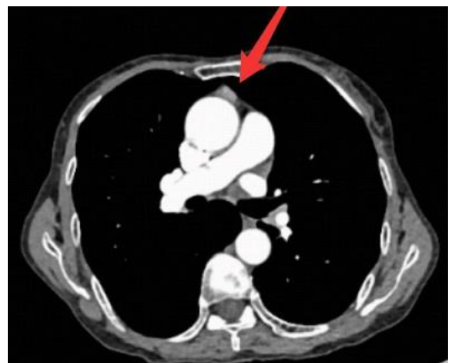


Fig. 2

2. Discussion

Thymic tumors are a relatively rare class of tumors, usually located in the anterior mediastinum, which are classified by the World Health Organization (WHO) pathological classification as thymic epithelial tumors, characterized by the combination of epithelial cells and lymphocytes. Its morphological diversity and pathological types are often related to T lymphocyte infiltration of different maturity, and obvious B-cell lymphoid groups rarely appear, while thymic tumors with a large number of B lymphocytes aggregating and forming germinal centers are extremely rare. [1] In particular, micronodular thymic carcinoma with B lymphocyte infiltration.

MNC was first reported in 1999 [2] by Suster, but no detailed studies have been made of the micronodular growth patterns associated with thymic carcinoma and the prominent lymphatic stroma. Named in 2012 by Weissferdt et al. [3]. The current incidence of MNC has not been specifically reported, and the literature [1 - 8] shows that the disease is more common in middle-aged and elderly people, and slightly more men than women. Most of the patients had no obvious clinical symptoms and were discovered incidentally during examination for unrelated diseases, and the cases reported in this report were also discovered incidentally by chest CT examination during the treatment of nephropathy. When some tumors are large, they compress neighboring organs and cause chest pain, chest tightness, dyspnea and other symptoms. Patients with thymomas often have a history of autoimmune disorders or tumors at other sites [9,10], which are less common in patients with MNC [2,5,8], who in this reported case are devoid of autoimmune diseases such as myasthenia and dermatomyositis. The radiographic findings of MNC are non-specific, and definitive diagnosis is based on pathologic features and exclusionary diagnosis of common mediastinal tumors.

The pathological diagnosis of MNC is complex and needs to be differentiated from other mediastinal tumors, such as A/AB thymoma, micronodular thymoma with lymphoid stroma (MNT) [11], lymphoepithelioma-like thymus carcinoma, malignant mediastinal lymph node metastasis, metastatic sarcoma and other tumor cells may show micronodular growth or tumors with a large number of B lymphocyte infiltration and aggregation in the interstitium, Therefore, microscopic tumor cell morphology and immunohistochemical staining are important means for diagnosis. Tumor cells with malignant cytology are micronodular growth, which contains a large number of prominent lymphatic stroma in the germinal center is a typical pathological feature of MNC, in addition, tumor cells can also be aggregated into sheet-like, cord-like and other structures, and molecular markers such as CD3, CD5, CD20, CD117 and TdT in immunohistochemical staining are helpful for the diagnosis and identification of MNC [7,8].

This reported case diagnosed thymoma before surgery, and the intraoperative freezing results also considered thymoma, but the postoperative pathology showed that the tumor cells were arranged in sheets or broad beams, separated by a large number of lymphoid tissues, with lymphatic follicles and germinal centers formed, and a small number of lymphocytes scattered in the epithelium were also seen. Immunohistochemistry showed tumor epithelial CK (+), P63 (+), P40 (+), CK19 (+), CD5 (+), CD117 (+), PAX-8 (a small amount of weak +), CD99 (+), EMA (-), CK20 (-), Ki67 The positive rate was about 30%; Lymphatic interstitial CD20 (mature B +), CD3 (mature T +). Combining HE morphology with

immunohistochemistry can diagnose MNC.

Due to the extreme rarity of MNC, there is currently no standard diagnosis and treatment plan and guidelines for this pathological type of thymic carcinoma. The treatment of MNC can be referred to other common thymic carcinomas [12], and the preferred treatment for thymic tumors is surgical resection, so once MNC is found to be assessed by a thoracic surgeon to determine resectability, surgical resection is preferred, and postoperative treatment is determined according to the postoperative tumor stage. For patients with complete resection of stage I, postoperative adjuvant therapy is not required. In terms of postoperative management, chest CT is reviewed every 6–12 months to monitor recurrence for 2 years, and then annually for 5 years. For patients with stage II. – IV. or incomplete resection, adjuvant radiotherapy can be used after surgery, with a total dose of 45–50 Gy, and close follow-up: CT is reviewed every 2 months for 2 years, and then reviewed once a year within 5 years [12]. The preliminary preoperative CT staging of this reported case was Masaoka-Kogal stage, so the surgical method with small trauma, wide field of view, and most importantly, complete removal of thymus and its surrounding fat was chosen: transxiphoid thoracoscopic thymic tumor enlargement resection [13,14]. After surgery, it was confirmed that the patient had been stage I Masaoka-Kogal, and the patient had completely removed the tumor during surgery, so regular follow-up was recommended after surgery. However, more clinical studies and long-term follow-up observations are needed to see whether postoperative adjuvant radiotherapy or chemotherapy is required for MNC with complete resection and stage greater than I [7]. Although MNC shows certain malignant behavior, its prognosis is better than other types of thymic cancer, and more research reports are needed on whether to directly refer to the current diagnosis and treatment protocols and guidelines for common thymic cancer. Studies [1,5] suggest that the good prognosis of this tumor is related to the proliferation of lymphocytes in the interstitium, which may indicate that the host has developed a certain immune response to the tumor cells. Therefore, we recommend relatively aggressive and prolonged postoperative follow-up for MNC. In this case, there was no tumor recurrence for 22 months after surgery, and the prognosis was good, but longer follow-up observation was still needed.

In short, the incidence of MNC is low and the pathology is complex, which is easily confused with other types of thymic tumors and leads to misjudgment of subsequent treatment plans, so clinical and pathologists should grasp its typical clinicopathological features, so as to formulate the correct treatment plan and follow-up plan, so as to avoid excessive treatment to increase the economic burden and unnecessary harm of patients.

References

- [1] Mneimneh WS, Gökmen-polar Y, Kesler KA, et al. Micronodular thymic neoplasms: case series and literature review with emphasis on the spectrum of differentiation. *Mod Pathol.* 2015;28(11):1415–1427.
- [2] Suster S, Moran CA. Micronodular thymoma with lymphoid B-cell hyperplasia: clinicopathologic and immunohistochemical study of eighteen cases of a distinctive morphologic variant of thymic epithelial neoplasm. *Am J Surg Pathol.* 1999;23(8):955–962.

- [3] Weissferdt A, Moran CA. Micronodular thymic carcinoma with lymphoid hyperplasia: a clinicopathological and immunohistochemical study of five cases. *Mod Pathol.* 2012;25(7):993-999.
- [4] Mao WJ, Li B. Micro-nodular thymic carcinoma with lymphoid stroma: a case report. *Chin J Minim Invasive Surg.* 2021;21(10):958-960.
- [5] Tateyama H, Saito Y, Fujii Y, et al. The spectrum of micronodular thymic epithelial tumours with lymphoid B-cell hyperplasia. *Histopathology.* 2001;38(6):519-527.
- [6] Nonaka D, Rodriguez J, Rollo JL, et al. Undifferentiated large cell carcinoma of the thymus associated with Castleman disease-like reaction: a distinctive type of thymic neoplasm characterized by an indolent behavior. *Am J Surg Pathol.* 2005;29(4):490-495.
- [7] Wang B, Li K, Song QK, et al. Micronodular thymic tumor with lymphoid stroma: a case report and review of the literature. *World J Clin Cases.* 2019;7(23):4063-4074.
- [8] Thomas de Montpreville V, Mansuet-Lupo A, Le Naoures C, et al. Micronodular thymic carcinoma with lymphoid hyperplasia: relevance of immunohistochemistry with a small panel of antibodies for diagnosis - a RYTHMIC study. *Virchows Arch.* 2021 Feb 24. Online ahead of print.
- [9] Bernard C, Frih H, Pasquet F, et al. Thymoma associated with autoimmune diseases: 85 cases and literature review. *Autoimmun Rev.* 2016;15(1):82-92.
- [10] Kumar V, Garg M, Goyal A, et al. Changing pattern of secondary cancers among patients with malignant thymoma in the USA. *Future Oncol.* 2018;14(19):1943-1951.
- [11] Marx A, Chan JK, Coindre JM, et al. The 2015 World Health Organization classification of tumors of the thymus: continuity and changes. *J Thorac Oncol.* 2015;10(10):1383-1395.
- [12] NCCN Clinical Practice Guidelines in Oncology. Thymomas and Thymic Carcinomas. Version 1. 2023.
- [13] Suda T, Ishizawa H, Nagano H, et al. Early outcomes in 147 consecutive cases of subxiphoid single-port thymectomy and evaluation of learning curves. *Eur J Cardiothorac Surg.* 2020;58(Suppl 1):i44-i49.
- [14] Jiang JH, Gao J, Zhang Y, et al. Modified subxiphoid thoracoscopic thymectomy for locally invasive thymoma. *Ann Thorac Surg.* 2020 Nov 27:S0003-4975(20)32009-9. Online ahead of print.